

Single vital tooth whitening

Linda Greenwall BDS MGDS RCS MSc MRD RCS FFGDP explains how to deal with whitening for a single tooth

Many patients more than ever are requesting tooth whitening. There are several reasons for this. Patients are adopting a more healthy lifestyle and thus want to whiten their teeth to give the appearance of being more healthy. White teeth are equated with youthfulness and many patients would like to look younger. The continued interest by the media in this subject has led to more information available about tooth whitening and thus patients are requesting these services from dentists. Some patients have started researching tooth whitening on the internet and are starting to gain a basic working knowledge about the subject.

Some patients when requesting whitening treatments are concerned that the teeth will become too white as they have seen comedy television programmes about this occurrence. These patients request natural enhancement of their existing shade, only a few shades lighter. Others request to have the whitest teeth and want the 'Hollywood White' look. It is thus important to ascertain from patients what they are trying to achieve with whitening and what is a realistic whitening goal. Some patients who have tetracycline staining have such dark discolouration that any improvement will be a bonus for them. These patients have a threshold of acceptability to be able to accept any minor improvements in the shade.

Some patients have just one tooth which has discoloured which could be the result of calcific metamorphosis (West 1997). The colour may vary from being subtly different from the adjacent tooth or there can be a marked contrast in the colour of the adjacent tooth. Some patients may not even be aware of the colour difference and it is important for the dentist to detect these colour differences.

History and diagnosis

Some patients when questioned as to the history of the discolouration will report some type of minor trauma that had occurred some years previously. The trauma could have been as simple as knocking the front tooth on the handle of a bicycle 10 years previously. The patient does not normally experience any pain from this discoloured tooth and the normal progression is that the tooth gradually became more yellow than the adjacent tooth over a period of years. Some patients may not be able to give a history of the tooth or may have forgotten any traumatic episode on the tooth. At the second appointment they may report that they vaguely recollect an incident of trauma.

Intra oral inspection of the tooth will normally reveal a yellow tooth with the colour either being uniform in colour of slightly darker at the cervical margin. The tooth is not normally tender to percussion or palpation.

Vitality testing

These teeth are normally vital but due to the trauma, the pulp chamber may be calcified or reduced in size. As a result there will be a slower response from the electric pulp tester. Normally the dial is turned right up to the end reading before the patient reports that they can feel the electric current vaguely. It is important to take time in testing the response of the patient as the patient will take time to register the reading. The same is true for the cold or ice test when placed on the tooth. It will eventually respond and the patient will report that they can feel the cold cotton wool on the tooth.

Radiographic assessment

A periapical radiograph will normally demonstrate the presence of pulp chamber and

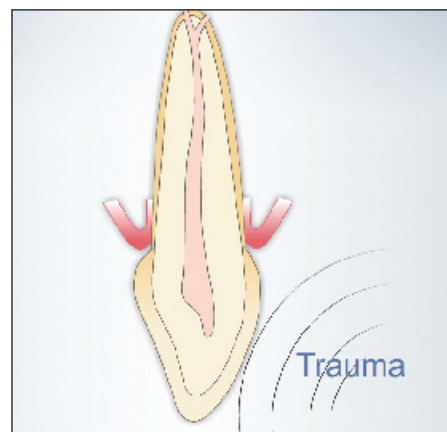


Figure 1: Mild trauma hitting the tooth

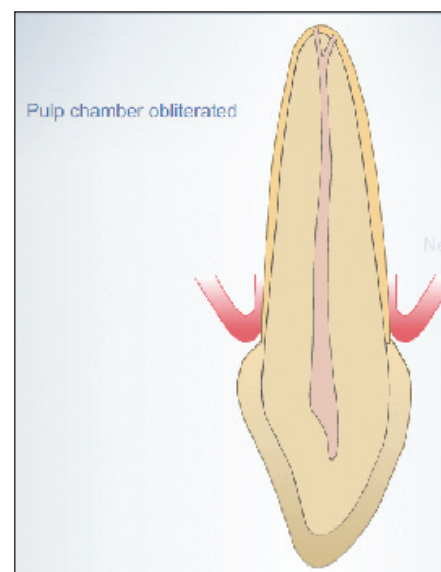


Figure 2: Tooth yellowing laying down of secondary dentine

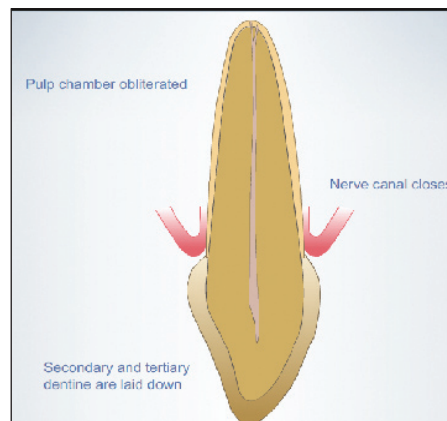


Figure 3: Single dark tooth; pathological process. Tertiary dentine being laid down



Linda is a specialist in Prosthodontics and Restorative Dentistry and runs a multi disciplinary private practice in Hampstead, London. She is editor in chief of Aesthetic Dentistry Today magazine and has written a book called 'Bleaching Techniques in Restorative Dentistry an Illustrated Guide' which was awarded Best New Dental Book of the Year 2001. Linda lectures all over the world on all aspects of combining Bleaching with Aesthetic and Restorative Dentistry. She also has a new book and interactive learning DVD called the Bleaching Business.

canal calcification or obliteration. The whole tooth is present and there is no evidence of any type of fracture in the tooth either in the crown of the root of the tooth (see Figure x). There is normally no periapical area present. The root of the tooth is in tact and there is no evidence of external or internal root resorption.

The pathological process

The usual process is that the minor trauma caused some type of bleeding within the tooth. This bleeding causes the formation of secondary and tertiary dentine to be laid down within the pulp canal. The secondary dentine is laid down regularly along the dentinal walls as a response to the trauma to protect the sensitive pulp tissue from further damage. This causes the pulp chamber and canal to gradually diminish in size until only a narrow root canal remains. It becomes calcified or sometimes even obliterated. Histologically, the pulps had increase in the amount of collagen and varying cell sizes (Lundberg and Cvek 1980). There seems to be no justification for root canal treatment of these teeth Cvek (2007).

Periapical radioluscencies have only been reported in 13-16% of teeth with traumatically induced pulp canal obliteration during observation periods of up to 20 years according to Jacobsen and Kerekes (1977). According to Cvek (2007) the periapical radiolucency which occurs later is associated with caries, inadequate crown restoration or new trauma.

Calcific metamorphosis (CM) can also be known as dystrophic calcification. It is seen commonly in the dental pulp after traumatic tooth injuries and can be recognised clinically as early as three months after injury. Calcific metamorphosis is characterised by deposition of hard tissue within the root canal space and yellow discoloration of the clinical crown. According to Amir et al (2001), opinion differs among practitioners as to whether to treat these cases upon early detection of CM or to observe them until symptoms or radiographic signs of pulpal necrosis are detected.

It is normally not necessary to do root canal treatment for these teeth. Most of the literature does not support endodontic intervention unless periradicular pathosis is detected or the involved tooth becomes symptomatic (Amir et al 2001). It may be advisable to manage cases demonstrating CM through observation and periodic examination and radiograph as necessary.

However, the discolouration in teeth with obliterated pulp chambers is not always caused by pigments from the blood degradation products but from the presence of the secondary and tertiary dentine which has been laid down after the trauma (according to Dahl and Pallensen

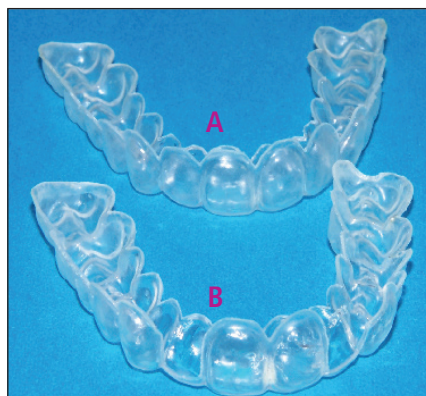

Figure 4: Bleaching tray design. A: Full arch tray. Single tooth bleaching can be undertaken in a full arch tray. B: Depending on the location of the single yellow tooth, windows can be cut adjacent to the dark tooth to prevent the adjacent teeth from getting too light, before the single dark tooth has managed to lighten sufficiently

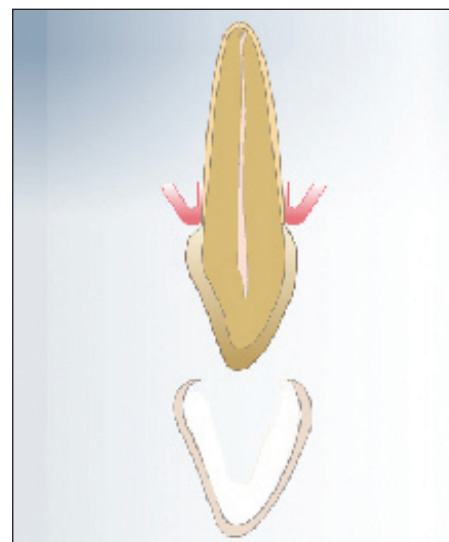


Figure 5: Start of bleaching treatment

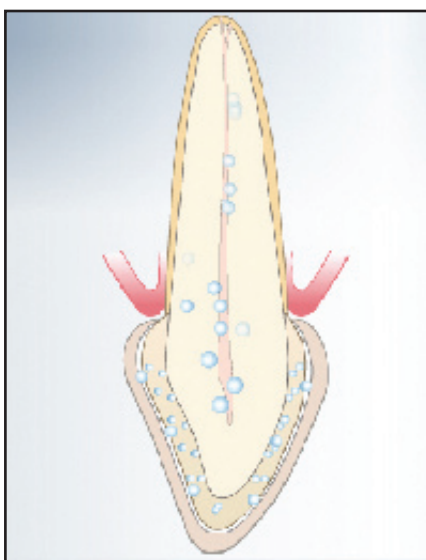


Figure 6: This figure shows the process of whitening as the oxygen moves through the tooth and through the pulp canal which has been narrowed due to the formation of secondary and tertiary dentine being laid down. After a period of about six weeks, the tooth starts to lighten

2007). It may be that the light being transmitted through such a tooth gives the appearance of it being darker.

The research and incidence of the occurrence

The response to minor trauma many years previously can result in 3.8% -27% of traumatised teeth can develop Dystrophic calcification (Amir et al 2001). Up to 16% of cases can develop pulp necrosis (according to Amir et al 2001) There were 51% which responded to normal Electric Pulp Testing and 40% were clinically and radiographically sound (Robertson et 1996) with Tertiary dentine formation occurring (Torneck 1990).

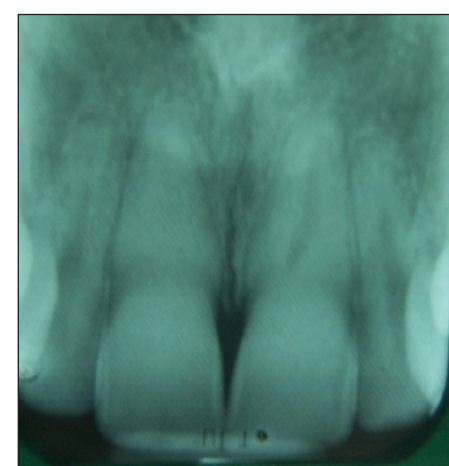


Figure 7: Radiograph of case 1 showing complete obliteration of the pulp chamber and the upper right central incisor due to trauma

The treatment

It is important to decide whether only the single dark tooth is to be bleached or whether the entire arch is to be bleached. It is more difficult to bleach the single dark tooth to get it to match and is easier to try to bleach the entire arch using a special protocol. If it is decided that only the single tooth should be bleached then a specially designed bleaching tray needs to be made. A full arch tray is first made and then a window is cut adjacent to the dark tooth on either side of the tooth to be bleached. If this is not done then the tooth next door will lighten quicker as the bleached moves rapidly to the adjacent tooth. This will result in the adjacent tooth being bleached quicker than the dark tooth and uneven bleaching will result.

Although some authors have suggested removing the coronal sclerotic dentine and utilising internal and external bleaching as necessary (Pedorella et al 2000), such extreme methods are not deemed to be necessary.

The protocol for bleaching the single tooth and the full arch

Normally a full arch scalloped bleaching tray is made. The upper teeth are bleached for two weeks using 10% carbamide peroxide to evaluate the speed and progress of the bleaching of the whole arch. Thereafter 20% carbamide peroxide gel is placed in the tray for adjacent to the single tooth for a period of four to six weeks or until the single tooth is matching all the upper teeth and they are all the same shade. Sometimes it may be necessary to continue whitening for a further two weeks after this. The progress of whitening the single tooth can be slow because of the nature of the dentine, which had been packed very densely from the secondary and tertiary dentine depositions. However there is little or no sensitivity experienced on this vital tooth during the whitening treatment.

Follow up and monitoring

It is important to undertake the appropriate monitoring at intervals which are deemed necessary to follow the progress of the whitening. This may be at two weekly or three weekly intervals or until the patient and dentist are satisfied with the result. Normally the shade of the single bleached tooth will retain well and regression is unusual and slow. It may be necessary to do a top up or maintenance treatment for the whole arch about three years later.

References

Cvek M (2007) Endodontic Management and the use of Calcium Hydroxide Chapter 22 in Traumatic Injuries to the teeth. 4th Edition Edited by Andreasen JO, Andreasen FM, Anderssen. Blackwell, Munksgaard Oxford London.

Denehy GE, Swift EJ Jr (1992) Single tooth whitening. Quintessence Int Sep;23(9):595-8.

Dahl JE and Pallesen U (2007) Bleaching of the Discoloured Traumatized Tooth. Chapter 33 in the Text book and Colour Atlas of Traumatic Injuries to the teeth. 4th Edition Edited by Andreasen JO, Andreasen FM, Anderssen. Blackwell, Munksgaard Oxford London.

Greenwall L.H (2001) Bleaching Techniques in Restorative Dentistry. Martin Dunitz Taylor

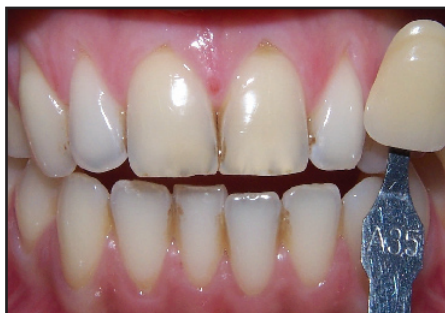

Figure 8: Case Number 1: This patient had two central incisors that were traumatised due to minor trauma from a swimming pool incident. See the radiograph which shows obliteration of the upper right central incisor and dentine bridge formation on the upper left incisor. The treatment involved using 10% carbamide peroxide for a period of two weeks on all the upper teeth and then 20% carbamide peroxide on the two central incisors for a period of three weeks. The patient experienced very little sensitivity during the bleaching treatment

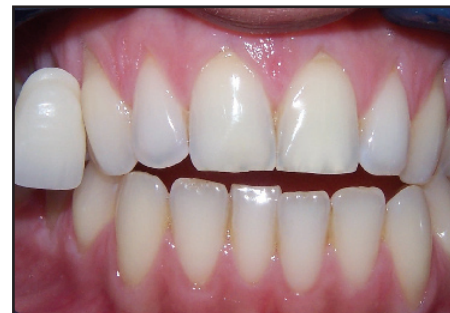

Figure 9: Case Number 1: The result after three weeks

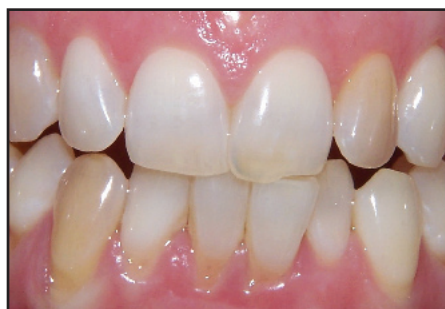

Figure 10: Case Number 2: This patient reported receiving a minor blow to the jaw due to a bicycle incident. She noticed over two months that the lateral incisor started yellowing, although she had initial pain for a week, the pain resolved. She visited her dentist who said no treatment was needed. She had naturally dark canine teeth present.

Treatment undertaken: Whitening all teeth for two weeks on the upper teeth 20% on 2 to lighten to match the other teeth. 20% gel was also placed on the 3|3 for the same time period to lighten and blend in with all the other upper teeth. This way even lightening of all the teeth was achieved

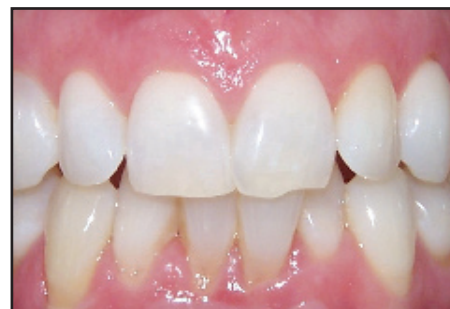

Figure 11: The result after whitening for Case 2

and Francis Publishing, London

Jacobsen I and Kerekes K. (1977). Long- term prognosis of traumatised permanent anterior teeth showing calcifying process in the pulp cavity. Scan J Dent Res 85: 588-98.

Lundberg M and Cvek M (1980) A Light Microscopy Study of pulps from Traumatized permanent incisors with reduced pulp lumen. Acta Odont Scand 38:89-94.

Pedorella CA, Meyer RD, Woollard GW (2000) Whitening of endodontically untreated calcified anterior teeth. Gen Dent May-Jun;48(3):252-5.

Torneck (1990) The clinical significance and management of calcific pulp obliteration. Alpha Omega 83(4):50-4.

Amir FA, Gutmann JL, Witherspoon DE (2001) Calcific Metamorphosis: a challenge in endo-

dontic diagnosis and treatment. Quintessence Int Jun;32(6):447-55

West JD (1997) The Aesthetic and endodontic dilemmas of calcific metamorphosis. Pract Periodontics Aesthet Dent .Apr;9(3):289-93; Robertson et al. J Endodontics 1996

**independent
seminars**

Linda Greenwall will be presenting a one-day seminar on the 'Brilliance of bleaching: New techniques and legal updates' on 14 December 2007 at the Royal College of Physicians, London. For more information, or to book your place, call 0800 371652, email seminars@fmc.co.uk or see www.independentseminars.com